Clinical status of COVID-19 Combined with CVD

Yundai Chen FCSC,FACC,FESC

Chinese PLA General Hospital

Beijing,China

Email:cyundai@vip.163.com

COVID-19 pandemic: Fatal threat to the global public health

- Up to 2020/03/18,confirmed cases surpass 201505 globally.
- Imported COVID-19 cases are now the major risk for China.

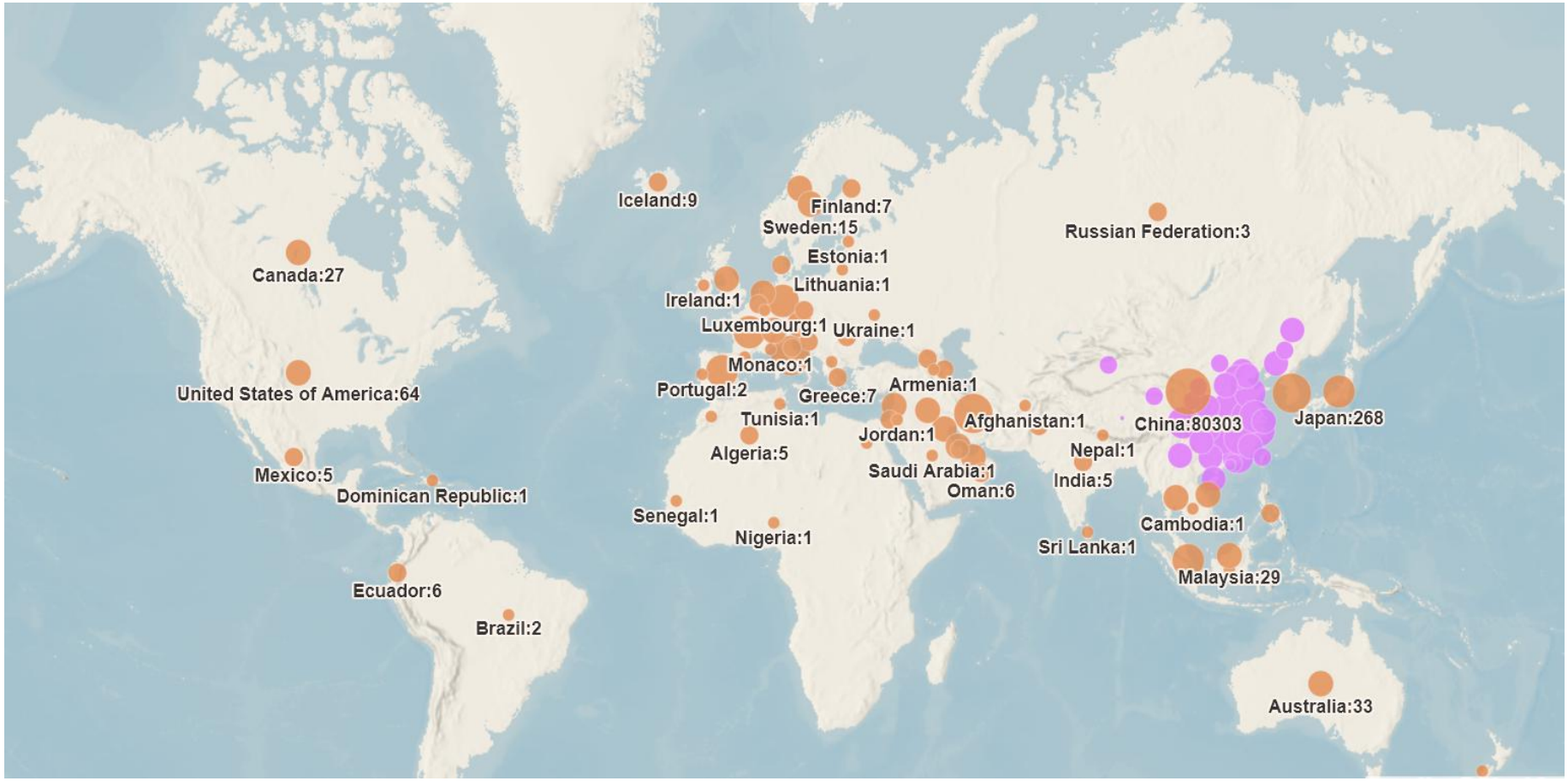

https://www.who.int

COVID-19 : Fatal threat to the global public health

- Patients with COVID-19 mostly present as normal (69.9%) and mild cases (4.5%), while the severe cases account for 25.5%.
- Mortality (2.3%) is lower than SARS (9.6%) and MERS (34%)

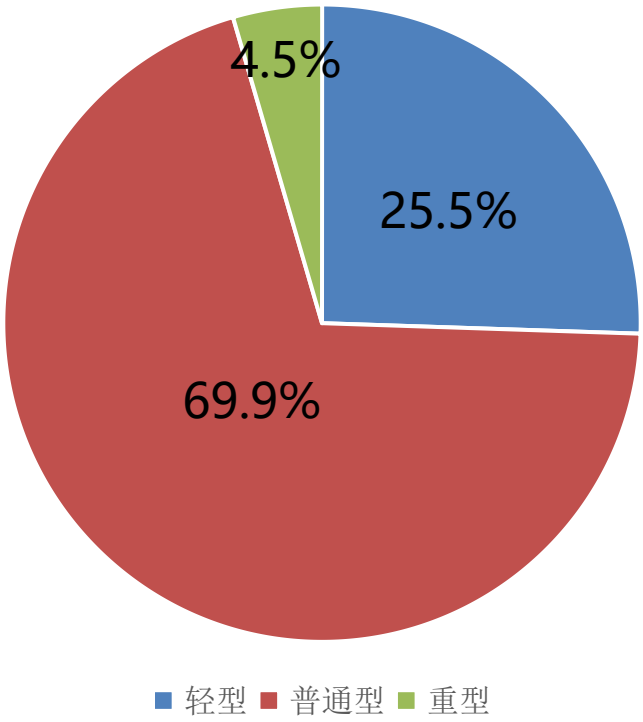

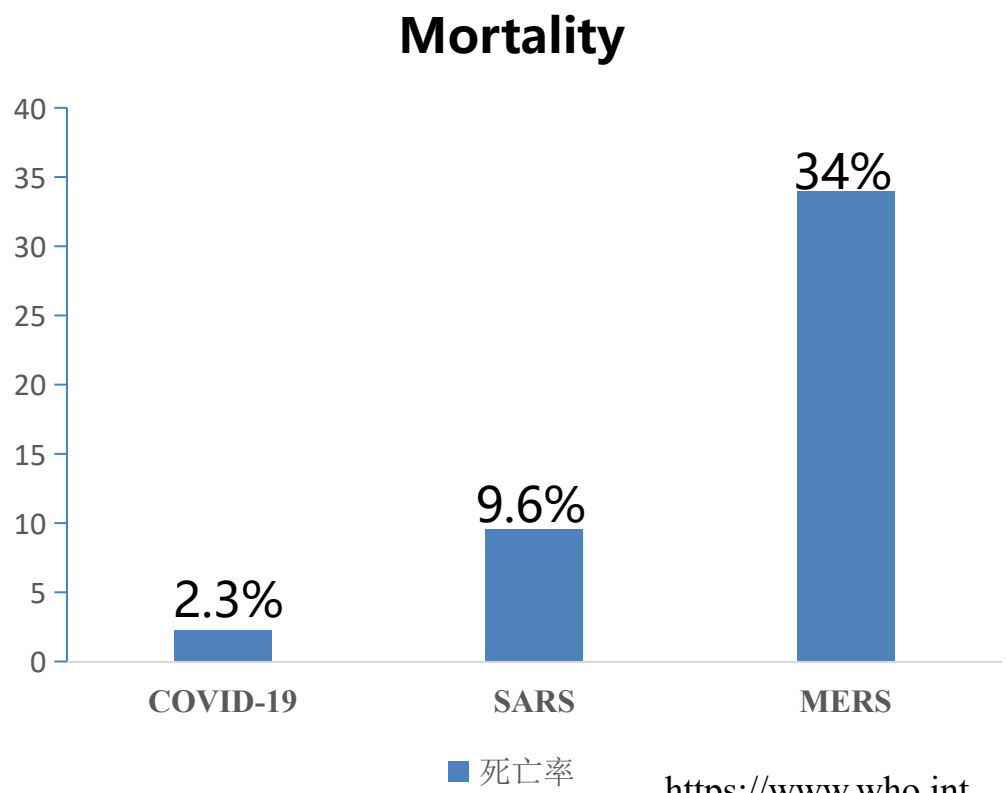

https://www.who.int

Underlying cardiac implications of COVID-19: cardiac injury in clinical studies

- An epidemiologic study including more than 70,000 subjects showed that COVID-19 patients combined with CVD had the highest fatality rate, up to 10.5%.

基本特征	确认病例(%)	死亡病例(%)	粗病死率(%)	观察人天	病死率密度(/10人天)
合计	44 672	1 023	2.3	661 609	0.015
基础性疾病[a]					
高血压	2 683(12.8)	161(39.7)	6.0	42 603	0.038
糖尿病	1 102(5.3)	80(19.7)	7.3	17 940	0.045
心血管疾病	873(4.2)	92(22.7)	10.5	13 533	0.068
呼吸道传染病	511(2.4)	32(7.9)	6.3	8 083	0.040
癌症	107(0.5)	6(1.5)	5.6	1 690	0.036
无	15 536(74.0)	133(32.8)	0.9	242 948	0.005
缺失	23 690(53.0)	617(60.3)	2.6	331 843	0.019

Chinese Journal of Epidemiology, 2020, 41(2): 145-151

Pathophysiology of SARS-CoV-2 remains unclear：Homologous with SARS and MERS

- The neucleotide of SARS-CoV-2 is 79% homological to SARS and 50% to MERS

The pathology mechanism and invading targets may be as well highly similar among coronaviruses

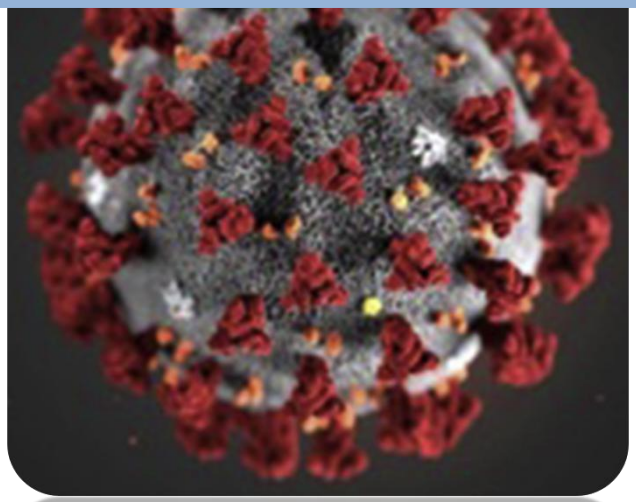

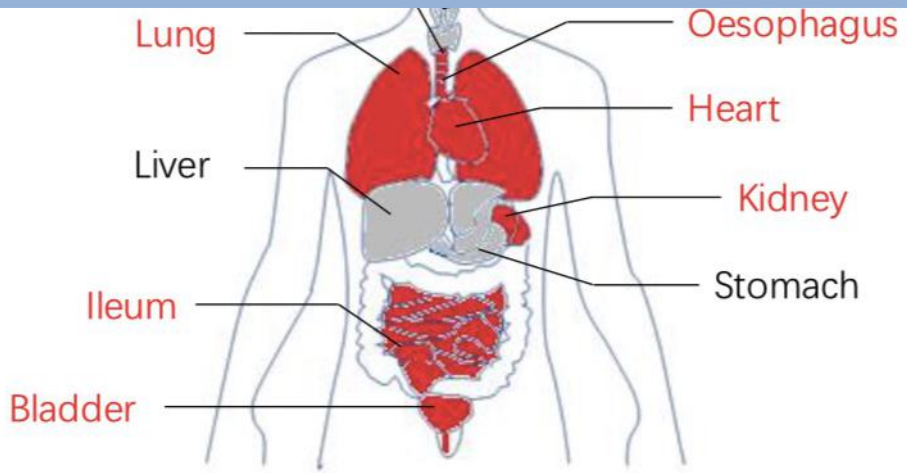

Lancet (London, England) 2020; 395(10223): 497-506;
Annals of Saudi medicine 2016; 36(1): 78-80.

Autopsies showed inflammatory changes in heart

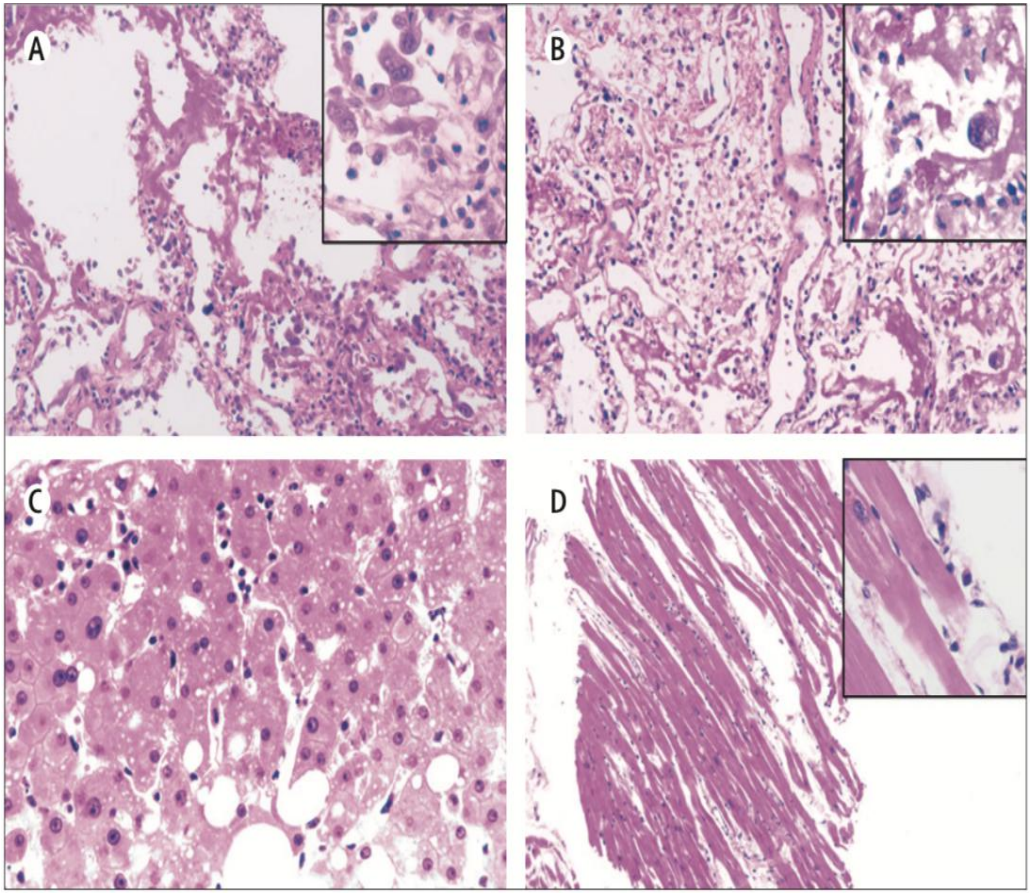

Figure 2: Pathological manifestations of right (A) and left (B) lung tissue, liver tissue (C), and heart tissue (D) in a patient with severe pneumonia caused by SARS-CoV-2

- There were a few interstitial mononuclear inflammatory infiltrates.
- Recent pathological biopsy revealed endothelial shedding, endometrial inflammation, and thrombosis in vessels.
- SARS-CoV-2 inclusions in the heart has not been reported, more evidence is needed

新型冠状病毒肺炎诊疗方案（试行第七版）

Xu Z, et al. *The Lancet Respiratory Medicine*. 2020.

Underlying cardiac implications of COVID-19: cardiac injury in clinical trials

- Common complications among the 138 patients from Zhongnan Hospital of Wuhan University included shock (12 [8.7%]), ARDS (27 [19.6%]), arrhythmia (23 [16.7%]), and acute cardiac injury (10 [7.2%]).

	No. (%)			
	Total (N = 138)	ICU (n = 36)	Non-ICU (n = 102)	*P* Value[a]
Complications				
Shock	12 (8.7)	11 (30.6)	1 (1.0)	<.001
Acute cardiac injury	10 (7.2)	8 (22.2)	2 (2.0)	<.001
Arrhythmia	23 (16.7)	16 (44.4)	7 (6.9)	<.001
ARDS	27 (19.6)	22 (61.1)	5 (4.9)	<.001
AKI	5 (3.6)	3 (8.3)	2 (2.0)	.11

JAMA. doi:10.1001/jama.2020.1585

Hypotheses of cardiac injury in COVID-19

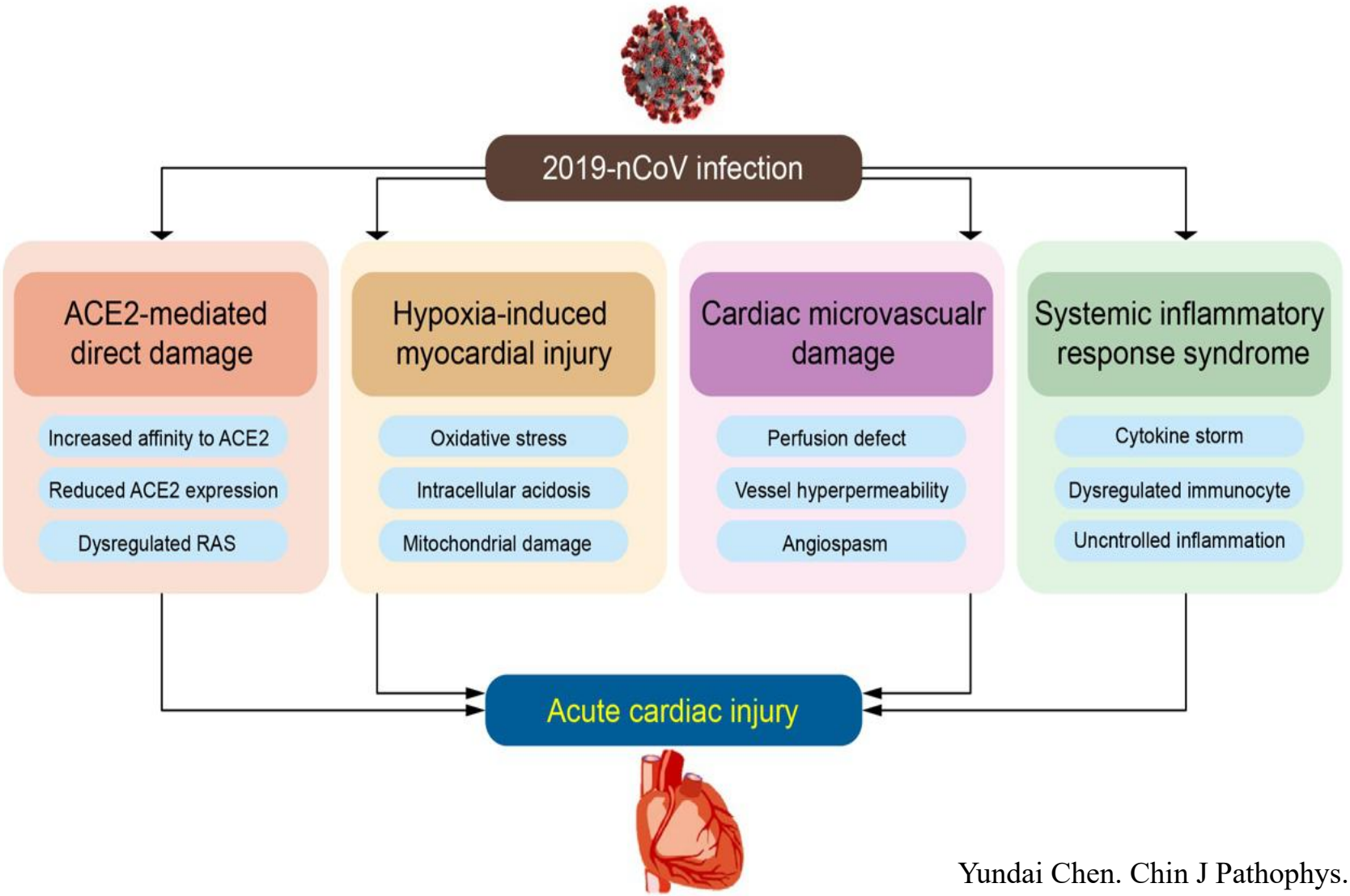

Yundai Chen. Chin J Pathophys. 2020；
Jinying Zhang. Nature Reviews. 2020

Current diagnosis and treatment of COVID-19

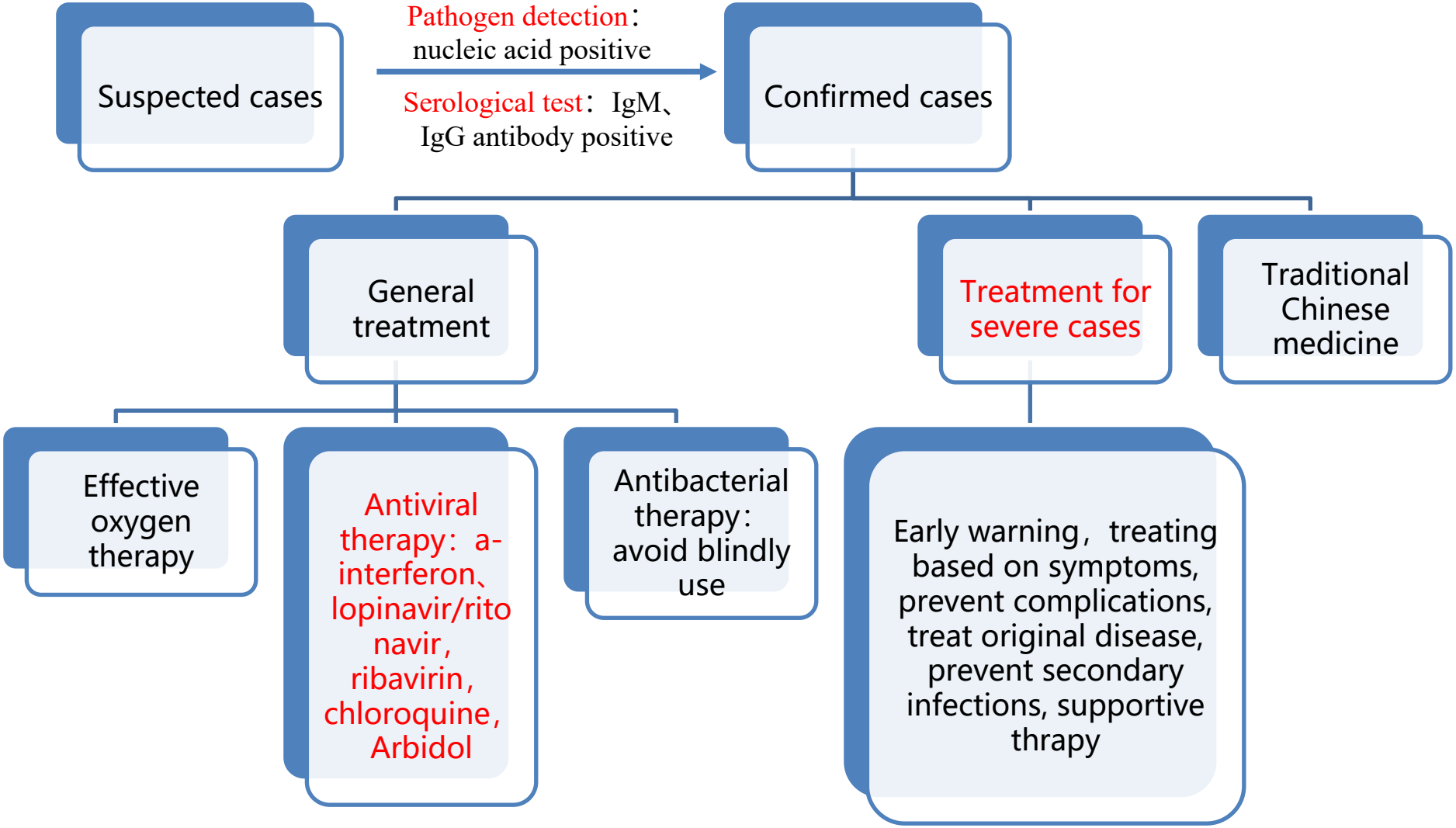

新型冠状病毒肺炎诊疗方案（试行第七版）

Management strategy for severe patients with COVID-19 and CVD

- Cardiac injury mainly occurs in severe patients, and mortality in severe cases accounts for as high as 49%
- SARS-CoV2 infection maybe an initiating factor, preventing transition to severe cases is crucial

Mild、normal cases

Clinical warning indexes

- Lymphocytes decrease progressively
- Inflammatory cytokines such as IL-6、CRP increase progressively
- Lactate presents an onging increase
- Pulmonary lesions progress rapidly in a short period

Severe cases

新型冠状病毒肺炎诊疗方案（试行第七版）

Obvious cardiac injury in critical ill patients with COVID-19

medRχiv THE PREPRINT SERVER FOR HEALTH SCIENCES

CSH Cold Spring Harbor Laboratory BMJ Yale HOM

Clinical and radiographic features of cardiac injury in patients with 2019 novel coronavirus pneumonia

Hui Hui, Yingqian Zhang, Xin Yang, Xi Wang, Bingxi He, Li Li, Hongjun Li, Jie Tian, Yundai Chen

doi: https://doi.org/10.1101/2020.02.24.20027052

Abstract:

Background: In December, 2019, a pneumonia associated with the Corona Virus Disease 2019 (COVID-19) emerged in Wuhan, China. Patients with cardiac disease have a higher fatality rate. However, the alerting clinical features of cardiac injury after COVID-19 infection yet to be determined. In this study, we investigated the correlation between clinical characteristics and cardiac injury of COVID-2019 pneumonia.

Methods: In this retrospective, single-center study, 41 consecutive corona virus disease 2019 (COVID-2019) patients (including 2 deaths) of COVID-2019 in Beijing Youan Hospital, China Jan 21 to Feb 03, 2020, were involved in this study. The high risk factors of cardiac injury in different COVID-2019 patients were analyzed. Computed tomographic (CT) imaging of epicardial adipose tissue (EAT) has been used to demonstrate the cardiac inflammation of COVID-2019.

Results : Of the 41 COVID-2019 patients, 2 (4.88%), 32 (78.05%), 4 (9.75%) and 3 (7.32%) patients were clinically diagnosed as light, mild, severe and critical cases, according to the 6th guidance issued by the National Health Commission of China. 10 (24.4%) patients had underlying complications, such as hypertension, CAD, type 2 diabetes mellites and tumor. The peak value of TnI in critical patients is 40-fold more than normal value. 2 patients in the critical group had the onset of atrial fibrillation, and the peak heart rates reached up to 160 bpm. CT scan showed low EAT density in severe and critical patients.

Conclusion: Our results indicated that cardiac injury of COVID-2019 was rare in light and mild patients, while common in severe and critical patients. Therefore, the monitoring of the heart functions of COVID-2019 patients and applying potential interventions for those with

- 41 consecutive COVID-2019 in Beijing YouAn Hospital, China Jan 21 to Feb 03, 2020, were involved .
- 2 (4.88%), 32 (78.05%), 4 (9.75%) and 3 (7.32%) patients were diagnosed as light, mild, severe and critical cases.
- COVID-19 patients with cardiac-related chronic diseases are more prone to be in the severe or critical cases.

Decreased pericardial adipose tissue is positively associated with the severity of COVID-19

- The elevation of TnI in critical patients is statistically significant compared with other groups
- CT threshold attenuation value of pericardial adipose tissue (EAT) decreased in the critical, severe and mild group, and they were lower than the light group.

	Light	Mild	Severe	Critical
Age (year)	31.00 (4.88%)	24.97(78.05 %)	68.25 (9.75%)	70.67 (7.32%)
White blood cell count (10^9/L, n=31)	3.07	4.15 (3.40-5.56)	5.85(4.50-12.87)	9.40(2.63-12.16)
Lymphocyte percentage (n=15)	34.70	28 (22.35-37.35)	16.60 (11.4-16.8)	12.70
C-reactive protein (mg/L, n=25)	1.20	14.10 (2.73-23.05)	55.72 (38.90-98.20)	191.00 (121.90-211.00)
Troponin I (ng/mL, n=20)	0.01	0.01	0.10	0.54 (0.05-5.90)
Creatinine (n=18)	53.00	69 (60-71.75)	78.00 (40.00-116.00)	129.00
SPO_2 (%, n=20)	--	97(95.38-97.4)	90.5(88.25-91.5)	64(60-76)

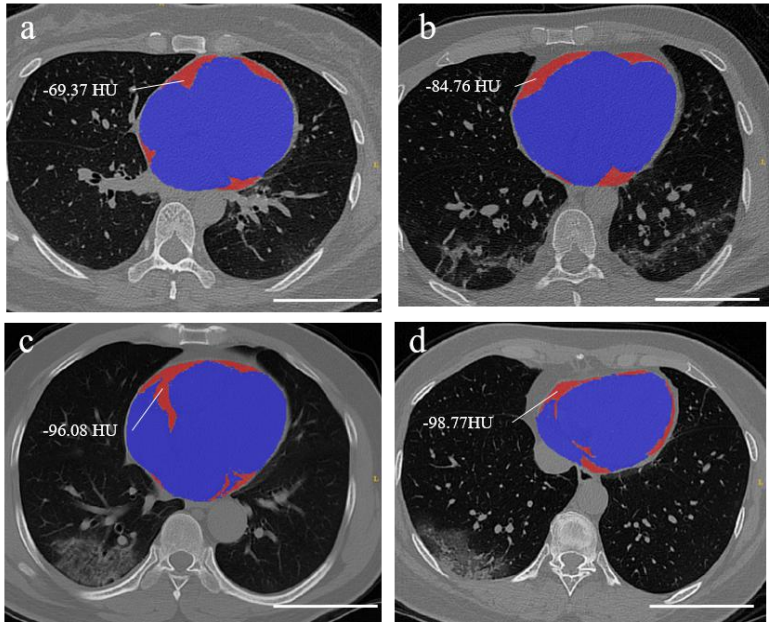

light (a), mild (b), severe (c) and critical (d)

Management strategy for severe patients with COVID-19 and heart dysfunction

Treat based on symptoms, prevent complications, treat pre-existing diseases, organ functional support in time

- Respiratory support： for critically ill patients with acute heart failure, ECMO should be applied in time
- Circulation support： sufficient fluid resuscitation, improve the microcirculation, pay attention to the balance of liquid
- Continuous renal replacement therapy（CRRT）： protect the kidney as early as possible, support the cardiac function
- Survivors plasma therapy: for critically ill patients with rapid progress
- Blood purification treatment： for cytokine storm
- immunotherapy： For patients with extensive lesions in lungs and elevated IL-6, Tocilizumab can be used

新型冠状病毒肺炎诊疗方案（试行第七版）

Drug options for patients with COVID-19 combined with CVD

中国介入心脏病学杂志 2020年 2 月第 28 卷第 2 期 Chin J Intervent Cardiol, February 2020, Vol 28, No. 2 · 107 ·

· 综述 ·

新型冠状病毒肺炎合并心血管疾病的临床问题探讨

陈韵岱 薛浩

【关键词】 新型冠状病毒； 新型冠状病毒肺炎； 心血管疾病
【中图分类号】 R197.32 R563.1

2019年底新型冠状病毒肺炎（简称新冠肺炎）在湖北省武汉市暴发流行，波及全国。截至2月22日全国累计确诊76 392例新冠肺炎，死亡2348例。新冠肺炎成为了严重威胁公众健康的传染性疾病。研究报道新型冠状病毒对心脏损伤有潜在影响，来自武汉临床资料分析发现，138例新冠肺炎患者中7.2%发生急性心脏损伤，16.7%发生心律失常；此外还发现心肌损伤标志物超敏肌钙蛋白I的水平重症监护病房（intensive care anit, ICU）患者高于非ICU患者[1]。另外，新近的两项研究也发现新冠肺炎患者均有不同比例的心脏损伤，表现为心肌损伤标志物的升高或心电图和超声心动图出现新的异常。而对于已有心血管疾病的患者并发症和死亡风险都明显增加。7万余新冠肺炎患者的流行病学研究显示[2]，合并心血管疾病患者死亡率高达10.5%，糖尿病为7.3%，慢性阻塞性肺病为6.3%，癌症为5.6%。因此，新型冠状病毒导致的心脏损伤以及对合并心血管疾病患者的预后值得关注。

此外，新型冠状病毒进入人体是通过与肺泡上皮细胞表面的血管紧张素转换酶2（angiotensin-converting enzyme 2, ACE-2）结合，进而使肺部受到损伤，引起肺功能衰竭。由于肾素-血管紧张素系统（renin angiotensin system, RAS）在心血管疾病的发生和发展过程中起重要作用，RAS抑制剂包括血管紧张素转换酶抑制药（angiotensin-converting enzyme inhibitor, ACEI）和血管紧张素Ⅱ受体阻滞药（angiotensin Ⅱ receptor blockers, ARB）在心血管疾病治疗中广泛使用，因此合并心血管疾病的新冠肺炎患者的治疗药物选择也是目前关注的焦点。

1 新型冠状病毒对心脏潜在的影响

新型冠状病毒是否对心脏有直接损伤尚不完全明确。近期对新冠肺炎患者尸检结果发现心脏组织中存在单核细胞炎性浸润，未发现新型冠状病毒对心肌的直接损伤[3]。由于此研究仅为单一样本的病理研究，因而不能排除病毒直接攻击心脏的可能。此外，研究发现新冠肺炎与重症急性呼吸综合征（severe acute respiratory syndrome, SARS）病毒的核苷酸同源性达78%，与中东呼吸综合征（middle east respiratory syndrome, MERS）病毒同源性达50%[4-5]，因此三种病毒的作用机制与损伤靶点可能高度相似。既往研究发现，SARS及MERS病毒感染都与急性心肌炎、急性心肌梗死和心力衰竭有关[6-7]，且尸检结果也证实35%患者心脏中可检测到SARS病毒RNA[8]。因此新冠肺炎感染同样可能会导致急性心肌炎，以及合并冠心病和心力衰竭患者急性事件发生。

过度免疫激活可能致新冠肺炎患者心肌损伤。研究发现，新冠肺炎患者外周血中CD4及CD8细胞数量大大减少，但其免疫细胞状态却被高度激活，主要表现为炎性细胞Th17增加和CD8细胞的高细胞毒性，说明患者存在严重的免疫损伤[3]。既往研究也发现，SARS患者存在不同程度的心脏舒张功能障碍，可能是由于过度免疫活化引起的心肌损伤[9]。因而应该重视免疫炎症过度反应对新冠肺炎患者心脏的影响。此外，新冠肺炎引起的全身炎症反应也可能引起冠状动脉斑块不稳定，终致心脏急性不良事件发生[7]。一项对121例SARS患者的研究显示，71.9%患者出现持续心动过速，但其与发热或氧饱和度降低无关，并有1例患者出现阵发性心房颤动[10]。因而新冠肺炎感染同样可能会导致心律失常发生或原有心律失常加重，其发生机制及严重程度仍需进一步研究。

"细胞因子风暴"是指机体感染微生物后引起体液中多种细胞因子（TNF-α、IL-1、IL-6、IL-12、IFN-α、IFN-γ、MCP-1和IL-8等）迅速大量产生的现象，是引起急性呼吸窘迫综合征和多脏器衰竭的重要原因。目前认为可能是导致重症新冠肺炎循环衰竭的主要原因。本次疫情中，有一部分新冠肺炎患者早期病情较轻，后期突然加重，最终不治。"细胞因子风暴"在SARS、MERS和流感中都是导致患者死亡的重要原因。当"细胞因子风暴"发生时全身细胞组织炎性渗出导致组织肿胀、细胞缺氧损伤，细胞损伤则氢键断裂，再灌注的氧气作为氧自由基和断裂氢键的蛋白质结合，导致缺血再灌注损伤。大量释放的炎症因子导致全身多器官的组织肿胀、血液灌注障碍，全身组织渗出使血浆减少，导致有效循环血流量锐减、循环衰竭，最终多脏器低灌注性功能衰竭。因此，早期对新型冠状病毒感染患者细胞因子的动态观察及干预需进一步研究明确。

2 影响新冠肺炎合并心血管疾病患者预后的可能原因

流行病学资料分析显示，心血管疾病可能影响新冠肺炎的预后。在新冠肺炎死亡病例中，22.7%合并有心血管基础疾病，

DOI：10. 3969/j. issn. 1004-8812. 2020. 02. 008
作者单位：100853 北京，解放军总医院第一医学中心心血管内科
通信作者：陈韵岱，Email：cyundai@vip.163.com

- ACEI/ARB: Whether patients should continue taking this remains controversial.
- Antiplatelet drugs： For CVD patients, continue taking the same medication, and hemorrhage should be observed strictly.
- Statins： monitoring the liver function closely.
- β-receptor blockers： if there is no hypoxia and airway spasms, selective β1-receptor blockers are recommended, and observe the pulmonary lesions.

Yundai Chen. Chinese Journal of Interventional Cardiology; 2020; 28(2):107-109

Potential interactions between antiviral drugs and cardiovascular drugs

- Interactions between antiviral drugs and cardiovascular drugs: Lopinavir and Ritonavir may increase the liver injury and cause the elevation of muscle enzyme if taken with some kinds of statins at the same time.
- Be alert to the direct or indirect damaging effects of antiviral drugs on heart: Chloroquine may induce sudden cardiac death, while Lopinavir and Ritonavir may lower the heart rate

Yundai Chen. Chinese Journal of Interventional Cardiology; 2020; 28(2):107-109

Coronavirus fulminant myocarditis

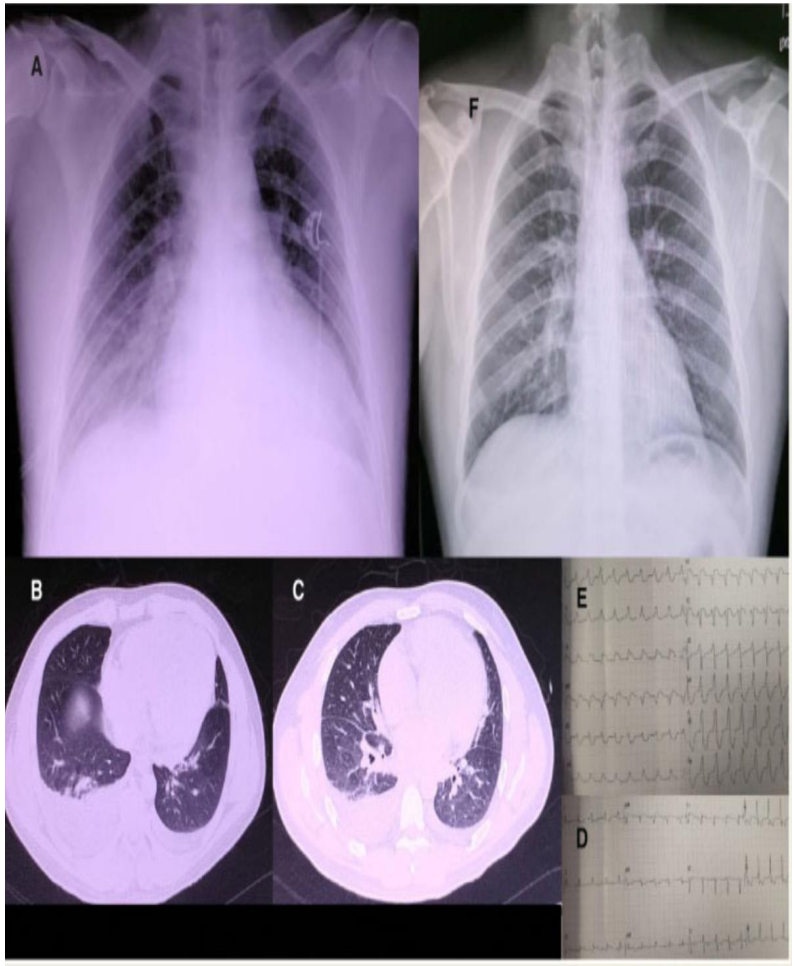

- Male, 37y, Chest pain and dyspnea for 3 days
- X-ray showed enlargement of the heart (A),
- Chest CT indicated pulmonary infection (B,C)
- ECG showed III and AVF ST segment elevation (D,E)
- Coronary angiography revealed no stenosis
- Test： TnT >10000 ng/L; CK-MB 112.9 ng/L
- Echocardiography showed decrease in ventricular systolic function, EF 27%
- Treatment: methylprednisolone, immunoglobulin, norepinephrine, diuretic, milrinone, piperacillin sulbactam
- One week later, X-ray showed normal size of heart (F); Echocardiography showed EF 66%

Hongde Hu, et al. European Heart J; doi:10.1093/eurheartj/ehaa190 .

COVID-19 combined with STEMI

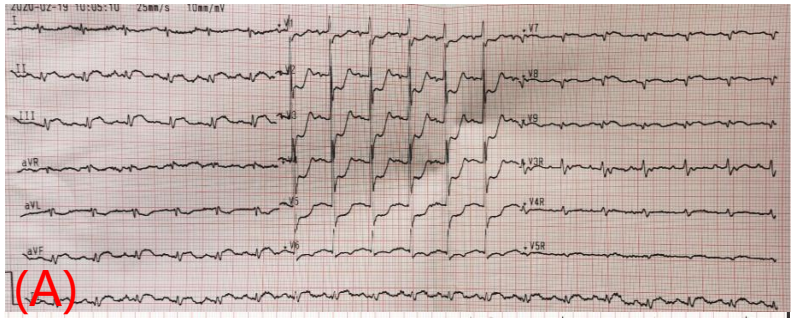

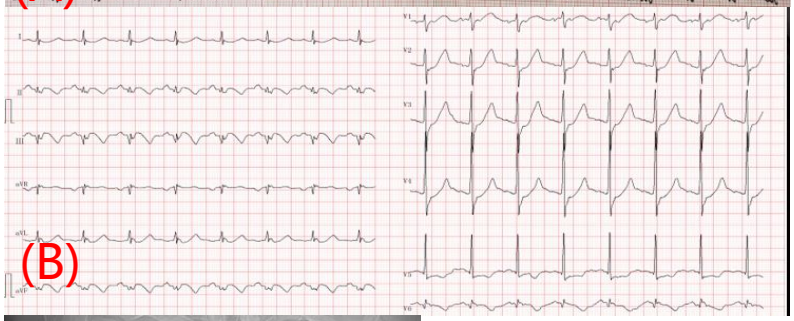

- Male, 60y, Dry cough for 1 week and chest pain for 26 hours
- History: Hypertension, smoking
- ECG showed elevated ST-segment in inferior leads, while decreased ST-segment in anterior wall. (A)
- Test： TnT 11500 ng/L; BNP 4121 ng/L
- Echo showed LAenlargement,abnormal left ventricular segmental wall motion, EF 45%
- Treatment: NO thrombolysis or PCI,only Antiviral, antiplatelet, and stable the plaques, supportive treatment with IABP
- 3 weeks later, chest pain occurred frequently, ECG showed severe ischemia in inferior wall as II, III and aVF leads (B)

Management strategy of COVID-19 combined with CVD

- Induce COVID-19 infection
- Avoid acute cardiac events (heart failure, ACS)

Early self-management

Diagnosis in time

- ECG、BP monitoring
- Early intervention
- Diagnosis of COVID-19 in time

Notice drug interactions

- Potential proarrhythmia
- Vasoactive agent induced acute events such as vasospasm
- Drug interaction induced liver injury

Therapy for severe cases

- Respiratory support: rectifying hypoxia
- Circulation support: maintain volume balance
- immunotherapy: Tocilizumab (TCZ)

Conclusion

? pathophysiology remains unclear

? no effective treatment yet

? early warning and treat for severe cases is crucial

- ✓ Although lack of direct evidence, the cardiac injury indeed exists in clinic
- ✓ Drug adjustment in time
- ✓ Prevent transition from mild cases to severe cases

Thank You For Listening